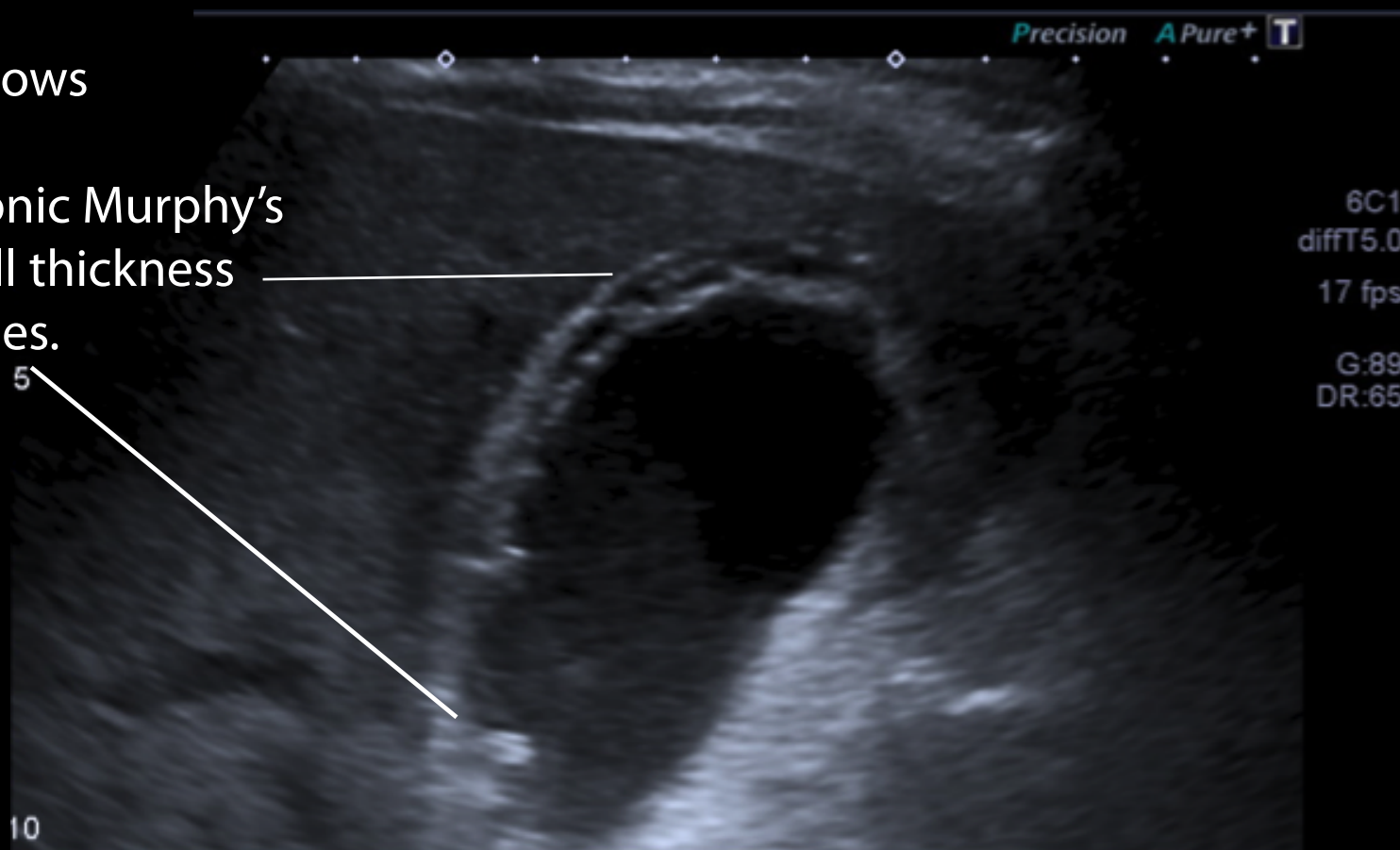


Radiological imaging of acute cholecystitis of two different patients

Ultrasound scan allows evaluation of focal tenderness (ultrasonic Murphy's sign), as well as wall thickness and identifies stones.



CT is not as sensitive as ultrasound in the detection of stones but is able to demonstrate wall thickening suggesting cholecystitis in the context of right upper quadrant pain.

